

Top 3 Differentials in gastrointestinal imaging : a case review by Rocky Saenz

C. Hommel

Service d'Hépatogastroentérologie, Cliniques universitaires Saint-Luc, UCLouvain, Brussels, Belgium

As the author states in the foreword, considering the top 3 differential diagnoses at the beginning of a workup is important for any practitioner. During medical studies we often learn by heart long lists of differential diagnoses and when residents start their training, they sometimes cannot see the wood for the trees, losing themselves in possible rare etiologies while the most frequent or urgent ones might be omitted. This book (1) offers a series of nicely illustrated cases with their corresponding top 3 differentials, the final diagnosis and is always accompanied by a paragraph of clinical pearls. The book's major chapter shows common hepatobiliary pathologies (91 pages). The remaining 190 pages illustrate splenopancreatic, gastrointestinal, mesenteric and/or vascular and abdominal wall findings. Illustrated imaging modalities encompass computed tomography (CT)-scan, magnetic resonance (MRI), plain radiographs and a few barium fluoroscopies. One of the odds with the paper book medium is that the reader cannot scroll through CT or MRI images, which in clinical practice is of course of utmost importance. The online version, which is accessible with a code provided in the printed version, could have contained dynamic versions of the radiologic studies to have a real added value. Unfortunately, it is just the digital, but identical version of the printed material.

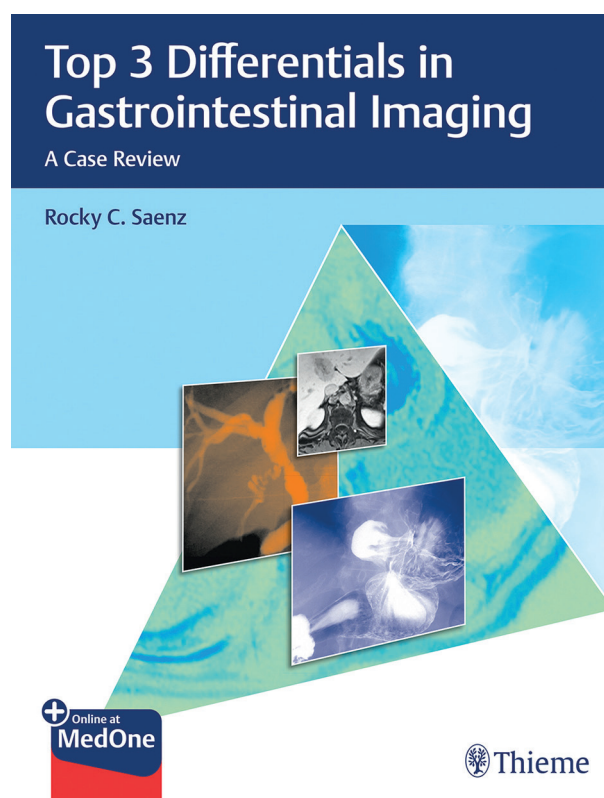
Despite the book's title and the author's credentials, the book aims to catch a broader audience than just radiologists interested in gastrointestinal imaging. Personally, as a clinician and gastroenterologist I would have liked to see more clinical data and a discussion about the complete work-up (not just the radiological one), maybe even treatment considerations.

The information provided is always referenced but the critical reader might find the sources a little redundant.

To sum up, this is a practical case series, which focuses on the top differential diagnoses of a radiological image and is of special interest for radiology trainees interested in gastrointestinal pathology, gastroenterology trainees or emergency physicians interested in having practical examples of common diseases.

Reference

1. SAENZ R.C. Top 3 Differentials in Gastrointestinal Imaging : A Case Review. Thieme Publishers New York/Stuttgart. 2019.



Cover image of the book.

Correspondence to : Dr Christophe Hommel, Service d'Hépatogastroentérologie, Cliniques universitaires Saint-Luc, UCLouvain, Avenue Hippocrate, 10, 1200 Brussels, Belgium.

E-mail : Christophe.Hommel@uclouvain.be

Submission date : 01/10/2019

Acceptance date : 01/10/2019

Acta Gastro-Enterologica Belgica, Vol. LXXXIII, January-March 2020